



Methicillin-Resistant *Staphylococcus aureus* Acute Osteomyelitis and Septic Arthritis of the Elbow in A Healthy Newborn

Sağlıklı Bir Yenidoğanın Dirseğinde Metisiline Dirençli *Staphylococcus aureus*'a Bağlı Gelişen Septik Artrit ve Osteomyelit

Midhat Kuşkaya¹(iD), Abdullah Ceylan²(iD)

¹ Clinic of Pediatrics and Pediatric Diseases, Dora Hospital, Istanbul, Turkey

² Clinic of Pediatrics and Pediatric Diseases, Region Pendik Hospital, Istanbul, Turkey

Cite this article as: Kuşkaya M, Ceylan A. Methicillin-resistant *Staphylococcus aureus* acute osteomyelitis and septic arthritis of the elbow in a healthy newborn. *J Pediatr Inf 2022*.

Abstract

Acute osteomyelitis with septic arthritis, which is uncommon in neonates, needs to be quickly diagnosed and treated to avoid devastating sequelae. We herein report a case of osteomyelitis with septic arthritis of the elbow caused by methicillin-resistant *Staphylococcus aureus* in a 24 day old neonate with no preexisting disease is reported. Physical examination revealed swelling and local heat around the right elbow accompanied by the limitation of spontaneous movements of the right arm and painful crying with careful passive arm motion. A magnetic resonance imaging study revealed the presence of joint fluid in the elbow joint and swelling of soft tissues. Arthrotomy was done with intravenous antibiotic therapy for six weeks to which the child responded well. As far as we know, our case presented is the youngest patient in literature presenting with acute osteomyelitis with septic arthritis of the elbow who was previously healthy.

Keywords: Newborn, osteomyelitis, septic arthritis, elbow, healthy

Öz

Akut septik artrit ve osteomyelit, yenidoğanlarda nadir görülen, sekel oluşumundan kaçınmak için hızlı tanı konulması ve tedavi edilmesi gereken hastalıklardır. Daha önce yayımlanmamış, 24 günlük sağlıklı yenidoğanda metisiline dirençli *Staphylococcus aureus*'a bağlı el bileğinde gelişen akut septik artrit ve osteomyelit olgusunu sunuyoruz. Fizik muayenesinde sağ kol dirseğinde lokal ısı artışı ve şişlik, sağ el spontan hareketlerinde kısıtlılık ve pasif el hareketlerinde ağrıya bağlı ağlama görüldü. Manyetik rezonans görüntülemeye dirsek ekleminde sıvı artımı ve yumuşak dokularda şişlik saptandı. Artrotomi ve sonrasında altı hafta devam eden intravenöz antibiyotik tedavisine iyi cevap alındı. Hastamız literatürde bildiğimiz kadarıyla öncesinde sağlıklı olup, dirsekte metisiline dirençli *S. aureus*'a bağlı gelişen en küçük akut septik artrit ve osteomyelit olgusudur

Anahtar Kelimeler: Yenidoğan, osteomyelit, septik artrit, dirsek, sağlıklı

Introduction

Osteoarticular infections are uncommon disorders in neonates. The diagnosis of osteomyelitis with septic arthritis in the newborn is more difficult than in the older children. Due

to the anatomy in neonates, osteomyelitis often co-exists with septic arthritis (1).

The diagnosis is often delayed, especially in neonates because of the paucity signs and symptoms. Early diagnosis and

Correspondence Address / Yazışma Adresi

Midhat Kuşkaya

Özel Dora Hospital, Çocuk Sağlığı ve Hastalıkları Kliniği,
İstanbul-Türkiye

E-mail: midhatkuskaya@gmail.com

proper treatment are essential to obtain good outcomes and avoid sequel. The most common causative organism is *Staphylococcus aureus*. Most of the cases result from hematogenous spread and typically occur in the metaphysis of long bones of lower extremities. (80%) Sites less commonly affected include the upper limbs, such as the shoulder and elbow (2,3). Moreover, osteoarthritis of the elbow in neonates is an extremely rare condition. The incidence is approximately 6% of all neonatal admissions (4). A complicated vaginal delivery, artery or vein umbilical catheterization, skin infection, urinary tract infections and transplacental infection have been described as risk factors (2). This case report presents a patient who had no such history.

Osteoarthritis of the elbow joint is rare, with few cases having been reported in the literature. Herein, we report a unique case of acute osteomyelitis and septic arthritis of the elbow caused by *S. aureus* infection in a neonate with no risk factors, who was previously healthy. A high index of suspicion and early diagnosis in this case has ensured excellent treatment outcome in this patient.

Case Report

A 24 day old, previously healthy male patient admitted to the Emergency Clinic of Cerrahpaşa Medical Faculty Hospital with following complaints: restlessness, decreased strength and movement in right arm and hand, inability to feed, weight loss and vomiting. On physical examination his weight was 3600 gr (11% weight loss). His laboratory findings were: C-reactive protein (CRP): 8 mg/L (upper limit 0.5 mg/L), blood urea: 110 mg/dL. After the primary assessment, he was referred to our neonatal intensive care unit (NICU) for further evaluation and treatment. The baby was delivered by elective C-section at 38 weeks gestation after a normal pregnancy to non-consanguineous parents. He was the second child of a 28 year old mother who had an uncomplicated pregnancy with no perinatal risk factors. The patient weighed 4040 g (75 p) at birth, length 52 cm (75 p), head circumference 34 cm (50 p). Apgar-scores were 8 and 9 after, respectively, 1 and 5 minutes. The physical examination on admission revealed arterial blood pressure of 65/30 mmHg, respiratory rate of 60-70/min, and body temperature of 36.4°C, oxygen saturation was 95-99%, heart rate of 140/min, heart was rhythmic and there was no additional sound or murmur. His liver and spleen were palpated 2-3 cm and 9-10 cm below the costae, respectively. He had a poor suck. Physical examination revealed swelling and local heat around the right elbow accompanied by the limitation of spontaneous movements of the right arm and painful crying with careful passive arm motion. Moro reflex was absent on the affected side. The other physical examinations were in normal limit.

Initial laboratory evaluation reveals the following values : Blood urea: 110 mg/dL (5-50 mg/ dL), creatinine 0.78 mg/dL (normal value), CRP: 98 mg/L (0-10 mg/L), white blood cells (WBC): 23200/mm³, hemoglobin (Hb): 10.5 gr/dL, hematocrit (Hct): 29.3%, alanine aminotransferase (ALT):205 IU/L, aspartate aminotransferase (AST): 135 IU/L, sodium: 132 mmol/L, blood gas: normal. Other laboratory results were normal.

A plain X-Ray of the abdomen in erect posture showed gas shadow, but no other pathological findings were revealed. On the complete abdominal ultrasound (US) a hepatosplenomegaly and a small liver hemangioma were detected. Transfontanelle ultrasonography was normal.

On the first day of hospitalization, the infant received empirical antibiotic therapy with ampicillin and cefotaxime for neonatal sepsis. The patient was tachypneic and he required supplemental oxygen via oxygen hood at 4 L/min oxygen for 24 hours. He was managed with intravenous fluid therapy to correct dehydration. The patient was then referred for an orthopaedic consultation. Orthopaedic examination revealed weakness of the right biceps and elbow flexors/extensors, diminished biceps reflexes on the right and the absence of Moro reflex in the right hand. After neurological consultation, the patient was referred for physiotherapy treatment.

The echocardiography showed normal except for the presence of the PFO (diameter 2 mm).

Blood cultures collected soon after admission were flagged as positive with methicillin-resistant *S. aureus* (MRSA). Therefore, his antibiotic therapy including ampicillin and cefotaxime was changed to vancomycin and cefotaxime.

On day 3, his tachypnea disappeared completely. On the same day, laboratory data included a CRP level of 54 mg/L, blood urea level of 40 mg/dL. Additionally, the sucking reflexes were recovered. The baby fed 8 x per day with 30-35 ml of breast milk. He showed a good response along with some weight gain (3750 gr). The levels of ALT/AST were decreased as 141 U/L, 81 U/L, respectively.

On the 10th day of admission, the blood tests showed: CRP: 47.5 mg/L, ALT: 50 U/L, AST: 35 U/L. However, limitation of active and passive movement, swelling, hotness, redness, tenderness of the right elbow persisted after two weeks of treatment and his CRP level was elevated as 87 mg/L. Thereupon, radiograph and magnetic resonant imaging (MRI) were performed at day 14 from intensive care unit hospitalization for the patient. Plain radiographs showed a thick, smooth periosteal reaction in the distal humerus and proximal ulna (Figure 1).

The radiograph of the affected side revealed joint space widening due to localized soft tissue oedema, intraarticular

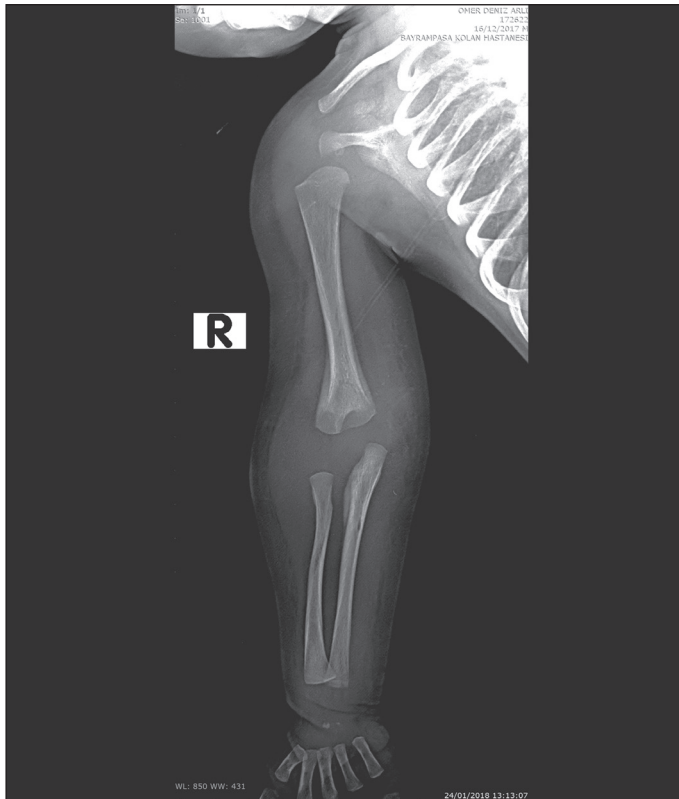


Figure 1. Plain radiograph of the right arm.

Plain radiograph shows joint space widening due to localized soft tissue oedema, intra articular accumulation of fluid. Soft tissue swelling around elbow joint due to synovial thickening was noted.

accumulation of fluid. Soft tissue swelling around the elbow joint due to synovial thickening was noted. There was smooth periosteal reaction in the anterior compartment of the muscle of the right arm (Figure 1). On MRI we found signs of osteomyelitis of the right distal humerus accompanying arthritis of the elbow joint, and there was also a high signal intensity of the soft tissue at the point of contact (Figure 2a-2b). Contrast-enhanced MRI of the elbow demonstrated contrast enhancement of the medullary bone marrow, oedema of the anterior right arm, thickening of synovial structures and marked high signal intensity in the soft tissue adjacent (Figure 3a-3b). However, the brachioradialis muscle was not affected.

On contrast-enhanced T1-weighted MR image, metaphyseal irregularity and periosteal reaction of the radius, ulna and humerus were identified. MRI also revealed multiple lymph nodes on the medial aspect of the right elbow; the largest one measured 6 mm. The largest lymph node in the right axilla, was measured around 2 cm. The findings suggested the diagnosis was septic arthritis with associated osteomyelitis and inflammatory changes in the soft tissues. In addition, coronal contrast-enhanced T1-weighted MR image of the elbow demonstrated a joint effusion, and spread of inflammation with a fluid collection in the adjacent muscles (Figure 3a-3b). A concern for acute compartment syndrome was raised.

After consultation with pediatric orthopedics, the patient was scheduled for an urgent right elbow arthrotomy and

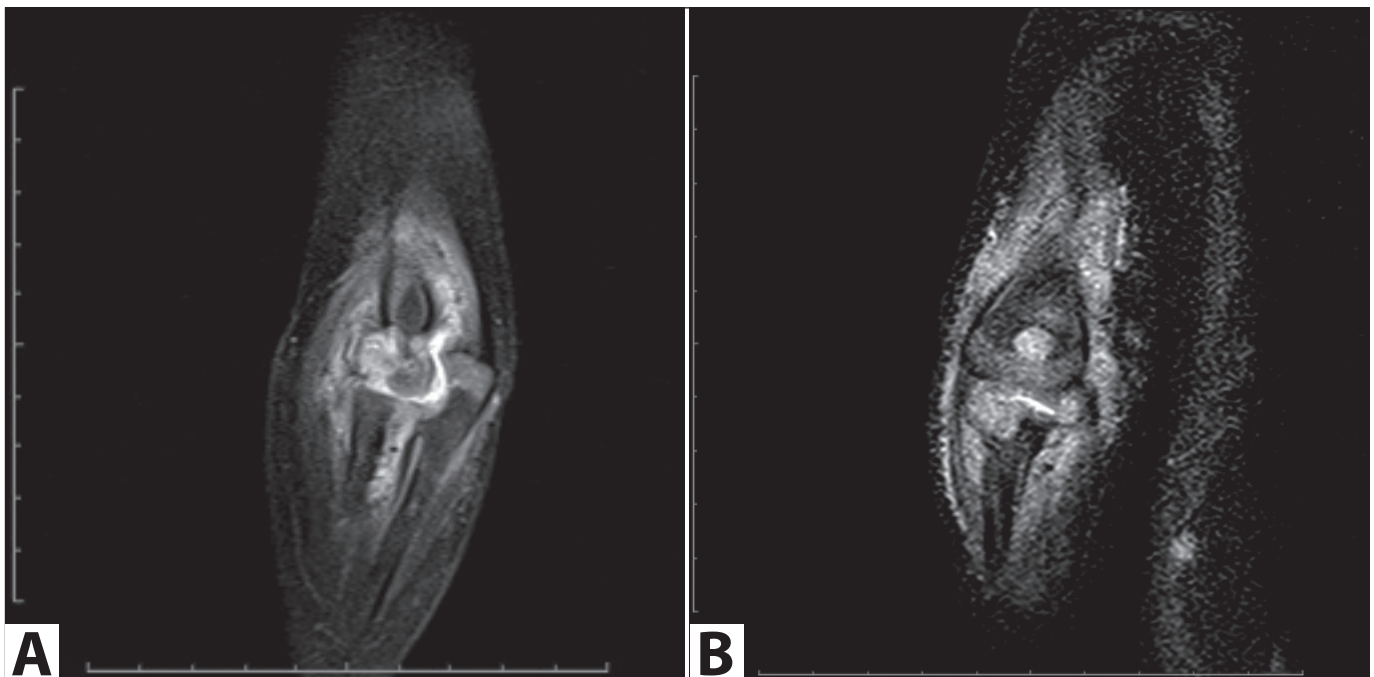


Figure 2. MRI of the right elbow (coronal section) shows a joint effusion, oedema of the anterior right arm, thickening of synovial structures and marked high signal intensity in the soft tissue adjacent. Periosteal reaction described in osteomyelitis seen on magnetic resonance imaging (MRI).

A. Coronal T2 fat sat view, **B.** Coronal STIR image.

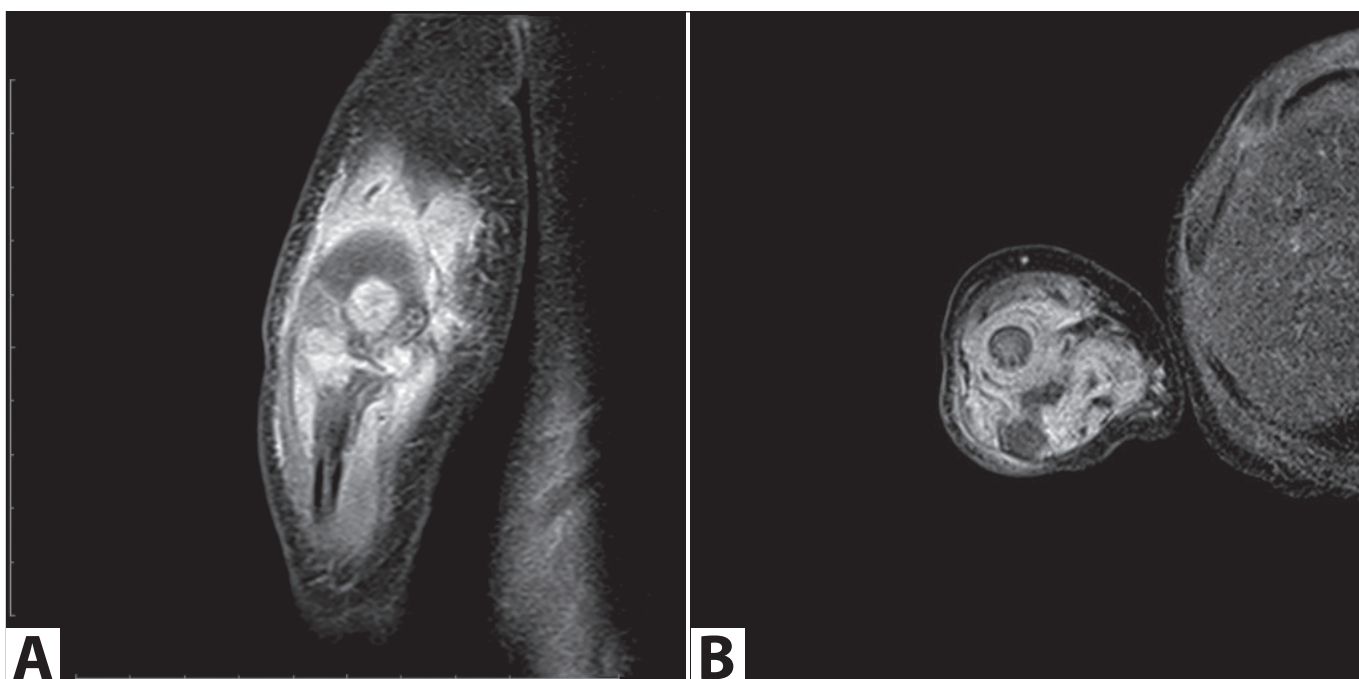


Figure 3. MRI-Elbow Joint (Contrasted) shows a joint effusion, contrast enhancement of the medullary bone marrow and spread of inflammation with a fluid collection in the adjacent muscles. **A.** Coronal T1-weighted fat-sat contrast-enhanced, **B.** Axial T1-weighted fat-sat contrast enhanced.

drainage. He was taken to the operating room and placed under general anesthesia. A lateral arthrotomy of the right elbow was performed and the elbow joint was thoroughly washed out with 1 L of isotonic saline solution, and the fluid was running clear. After incision of the capsule samples were taken of the synovial fluid for microscopy and culture. The incision was closed and the patient left the operating room with a drain on his right elbow. He was followed up in the intensive care unit (NICU). As a result, treatment with vancomycin and cefotaxime was continued for total six weeks. The patient responded well to antibiotic therapy. On the 3rd week after admission, the patient's CRP level decreased. At discharge CRP was within normal range. Synovial inflammation and effusion also decreased on MRI. Blood and urine culture showed no growth. Liver function tests and other biochemistry results were normal. The patient was achieved successful treatment and discharged from hospital with no sequel, and will be followed up in the outpatient clinic. He also was well in clinic with normal arm movements and the Moro reflex of right hand was significantly improved.

Discussion

Osteoarticular infections in the neonatal period are uncommon. Although acute osteomyelitis with septic arthritis is rare in neonates, it might result in severe sequelae such as joint destruction and disturbances in bone growth if it is not diagnosed and treated early (5). Neonates are relatively immunocompromised due to their immature immune system,

and are susceptible to osteoarticular infections. Osteomyelitis with septic arthritis in the neonate is a complex pathology, with non-specific symptoms. Compared to older children, there are fewer clinical signs and the diagnosis of osteomyelitis and arthritis may therefore be harder to make (5). The most common consistent finding is absence of spontaneous movements of the involved limb (pseudoparalysis) (6). Common clinical presentations of elbow osteoarthritis in 77 neonates were reported as were pain (90%), motor disability (96%), tenderness (75%), and erythema (45%) (7). Indeed, in our patient, the most impressive signs that led us to a diagnosis were a swelling of the right elbow, tenderness, pseudoparalysis and pain during passive movements.

Most of the cases result from hematogenous spread and typically occur in the metaphysis of long bones of lower extremities. (80%) Sites less commonly affected include the upper limbs, such as the shoulder and elbow.

To our knowledge, the report of osteomyelitis with septic arthritis of the elbow in a healthy neonate is very rare. There have been singularly few cases of neonatal osteomyelitis with septic arthritis of the elbow reported in literature. A retrospective chart review of 77 neonatal patients with osteoarthritis by Berberian et al. in 2010 demonstrated only six cases of osteoarthritis of the elbow (4).

Somford et al. in 2015 reported a case of osteomyelitis with arthritis of the right ankle and the left elbow joint in a 26 weeks premature neonate (8).

Hass et al. in 2014 reported a case of septic arthritis of the elbow in a nine month-old girl due to *S. aureus* (9).

The children in these studies had an underlying disease and risk factors to make them susceptible to infection, whereas in the current report, no associated pathology was identified.

Abdullah Saleh Al Nafeesah in 2015 published a case of *Salmonella* septic arthritis of the elbow in a healthy 11 month old female infant due to nontyphoidal *Salmonella* successfully treated with surgical drainage (10).

As far as we know, our case presented is the youngest patient in literature presenting with osteoarthritis of the elbow who was previously healthy.

A complicated vaginal delivery, artery or vein umbilical catheterization, skin infection, urinary tract infections and transplacental infection, preterm birth have been described as risk factors. This case report presents a patient who had no such history.

It has been reported that the most frequently isolated organism in neonates with osteomyelitis is *S. aureus* (SA). When it comes to septic arthritis, the most common causative organisms are *S. aureus*, group B streptococcus, coagulase-negative staphylococci, gram-negative bacilli (2,3). *Kingella kingae* is also an infrequent cause of septic arthritis, particularly during childhood (3). In agreement with the literature, *S. aureus* was grown in blood culture in our patient.

In a review of more than 300 cases with neonatal osteomyelitis, the male newborns were predominated over the female ones (11,12).

Osteomyelitis often co-exists with septic arthritis in more than half of neonates as a result of a unique vascular anatomy characterized by the presence of vascular connections between the metaphysis and the epiphysis. Early diagnosis and proper treatment are essential to obtain good outcomes and avoid sequel. The management is through antibiotic treatment accompanied by surgical drainage. In general, isolated septic arthritis should be treated for at least 2 to 3 weeks, but septic arthritis due to *S. aureus* usually requires 4 to 6 weeks of antibiotic therapy. In our case, the patient was treated with six weeks of intravenous vancomycin (45 mg/kg per day divided in 3 doses) cefotaxime (200 mg/kg per day divided in 3 doses). Children who do not respond to adequate antibiotic therapy may require surgical incision and drainage (13).

Open arthrotomy is the definitive treatment for the disease. Decision to open the joint should be taken as soon as the conservative treatment failed to relieve the symptoms and intraarticular pressure of the joint. Deshpande et al. in 2004 reviewed 15 cases of neonatal septic arthritis of hip and sug-

gested that arthrotomy should be as early as possible, especially on an emergency basis, instead of waiting 72h (14).

Laboratory studies are also helpful in diagnosing osteomyelitis with septic arthritis. C-reactive protein is a suitable marker for the diagnosis of osteoarthritis, and it can be used for the early detection of infection and guiding of antibiotics therapy. In the presented case, the CRP increased to 98 mg/L and then decreased during therapy to 0.5 mg/L. Other lab findings, such as the number of leukocytes, ESR and Procalcitonin (PCT) can be monitored to assess progression of disease. In the presented case, the WBC increased to 23200/mm³ and then decreased during therapy to 6200/mm³. On admission, PCT and ESR levels were 1.20 ng/mL and 68 mm/h, respectively. During the reexamination before discharge, PCT and ESR decreased to 0.2 ng/mL and 3 mm/h, respectively.

Computer tomography scan and MRI are other modalities that may be used to confirm the diagnosis. Radiography is usually the first radiological investigation in a neonate with suspected osteoarthritis. However, according to Deshpande, radiographic resolution lags behind clinical resolution of infection, so radiographs may not be useful in monitoring the clinical course (14). Magnetic resonance imaging scan is the most sensitive type of imaging test. Early changes in osteomyelitis can be detected on MRI and it also allows identifying subperiosteal abscess, soft-tissue infection and joint effusion. Our patient's MRI images revealed the presence of joint fluid in the elbow joint and swelling of soft tissues (Figure 2,3). Our patient had a rare presentation of acute osteomyelitis with septic arthritis of the elbow. There have been singularly few cases of similar documented cases (8-11) and they were associated with risk factors such as preterm birth, umbilical catheterization or underlying disease.

Conclusion

As indicated in the present case report, osteomyelitis with septic arthritis of the elbow is very rare among healthy children. Treatment requires both surgical drainage and administration of adequate antibiotics. Although rare, neonatologists, pediatricians and pediatric orthopedists should pay more attention to any diagnostic clues for osteoarthritis in healthy newborn infants, including its imaging findings and the results of blood cultures. A high degree of suspicion and careful observation of the newborn are essential for early diagnosis and subsequent successful treatment of the disease. Timely antibiotic therapy and proper surgical interventions led to a successful outcome in this case.

Acknowledgement

We would like to thank radiologist MD Ozgur Cakir for his contributions to this study.

Informed Consent: Patient consent was obtained.

Peer-review: Externally peer-reviewed.

Author Contributions: Concept - MK; Design - MK; Supervision - MK, AC; Resources - MK, AC; Data Collection and/or Processing - MK, AC; Analysis and/or Interpretation - MK, AC; Literature Review - MK, AC; Writing - MK; Critical Review - MK, AC.

Conflict of Interest: No conflict of interest was declared by the authors.

Financial Disclosure: The authors declared that this study has received no financial support.

References

1. Offiah AC. Acute osteomyelitis, septic arthritis and discitis: differences between neonates and older children. *Eur J Radiol* 2006;60:221-32. <https://doi.org/10.1016/j.ejrad.2006.07.016>
2. Mc Pherson DM. Osteomyelitis in the neonate. *Neonatal Netw* 2002;21(2):9-22. <https://doi.org/10.1891/0730-0832.21.1.9>
3. Yagupsky P. *Kingella kingae* infections of the skeletal system in children: diagnosis and therapy. *Expert Rev Anti Infect Ther* 2004;2(5):787-94. <https://doi.org/10.1586/14789072.2.5.787>
4. Berberian G, Firpo V, Soto A, Lopez Mañan J, Torroija C, Castro G, et al. Osteoarthritis in the neonate: risk factors and outcome. *Braz J Infec Dis* 2010;14(4):413-8. [https://doi.org/10.1016/S1413-8670\(10\)70085-4](https://doi.org/10.1016/S1413-8670(10)70085-4)
5. Bos CF, Mol LJ, Obermann WR, Tjin a Ton ER. Late sequelae of neonatal septic arthritis of the shoulder. *J Bone Joint Surg (Br)* 1998;80:645. <https://doi.org/10.1302/0301-620X.80B4.0800645>
6. Friederiksen B, Christiansen P, Knudsen FU. Acute osteomyelitis and septic arthritis in the neonate. *Eur J Ped* 1993;152:577-80. <https://doi.org/10.1007/BF01954084>
7. Bulbul A, Uslu HS. Yenidoğan acilleri; Yenidoğanda Osteoartiküler Enfeksiyonlar, in: *Neonatal emergencies; osteoarticular infections in the newborn. İstanbul Tıp Kitabevi: İstanbul, 2014; pp: 297-300.*
8. Somford MP, Hulbers MHW, Schuppen S, Struijjs PAA, Van Lee R. Multifocal osteomyelitis in a neonate. *J Orthop Res Physiother* 2015;1(3):1-4. <https://doi.org/10.24966/ORP-2052/100015>
9. Tabea H, Mark SG, Carlo C. Septic arthritis of the elbow with streptococcus pneumoniae in a 9 month-old girl. *BMJ Case Report* 2014;9-12. <https://doi.org/10.1136/bcr-2014-205204>
10. Al Nafeesah AS. Nontyphoidal salmonella septic arthritis of the elbow in a healthy infant. *PAMJ* 2015;22:357. <https://doi.org/10.11604/pamj.2015.22.357.7680>
11. Fox L, Sprunt K. Neonatal osteomyelitis. *Pediatrics* 1978;62:535-42. <https://doi.org/10.1542/peds.62.4.535>
12. De Boeck H. Osteomyelitis and septic arthritis in children. *Acta Ortho Belg* 2005;71:505-15.
13. Sharif I. Current treatment of osteomyelitis. *Ped Rev* 2005;26:38-9. <https://doi.org/10.1542/pir.26.1.38>
14. Deshpande SS, Taral N, Modi N, Singrakhia M. Changing epidemiology of the neonatal septic arthritis. *J Orthop Surg (Hong Kong)* 2004;12:10-3. <https://doi.org/10.1177/230949900401200103>